

Navigating the Diagnostic Dilemma: Thrombotic Thrombocytopenic Purpura Presenting with Rhabdomyolysis in an Adolescent

KISHOR KHILLARE¹, SHEETAL NANDHA KISHORE², JAGANNATH S DHADWAD³,
JANVI PANCHAL⁴, DHAIRYA SANGHANI⁵



ABSTRACT

Thrombotic Thrombocytopenic Purpura (TTP) is a rare and potentially fatal disorder that causes the formation of small blood clots in the microvasculature, leading to symptoms such as low platelet count, Microangiopathic Haemolytic Anaemia (MAHA), fever, renal dysfunction and sometimes neurological issues. While the classic presentation includes a combination of five key symptoms, not every patient exhibits all of them, which can complicate diagnosis. TTP may be triggered by a range of factors, including infections, autoimmune conditions, or, in some cases, medications and vaccines. This case report details the clinical journey of a 17-year-old male who presented with a combination of symptoms, including rhabdomyolysis, Acute Kidney Injury (AKI) and haemolytic anaemia, which ultimately led to a diagnosis of TTP presenting with rhabdomyolysis. TTP along with rhabdomyolysis is not commonly seen. The complexity of the case was heightened by overlapping signs of infection, renal damage and haemolysis, which made it difficult to identify the underlying cause. This report emphasises the importance of considering TTP in patients with unexplained multiorgan failure and rhabdomyolysis and highlights the critical role of early treatment with plasmapheresis, steroids and supportive care in achieving a positive outcome, even in the face of a complex clinical presentation.

Keywords: Creatinine phosphokinase, Haemolytic anaemia, Plasmapheresis

CASE REPORT

A 17-year-old male presented to the emergency department with complaints of fever, which was high-grade in nature, associated with chills for four days. He reported an acute onset of breathlessness, bilious vomiting and generalised abdominal pain, along with yellowish discoloration of the skin and generalised muscle pain, weakness and decreased urinary output, with dark reddish-brown coloured urine for the past two days. The patient did not report any significant past or personal history.

The patient and his parents gave consent for a physical examination and further investigations. Upon physical examination, the patient was afebrile, appeared dehydrated, drowsy and exhibited pallor and icterus. He had tachypnoea with a respiratory rate of 40 breaths per minute and a pulse rate of 96 beats per minute. His blood pressure was 110/80 mmHg and his oxygen saturation was 88% on room air. He was started on five liters of oxygen, after which he maintained a saturation of 98%. Abdominal examination revealed diffuse tenderness

with guarding, while other systemic examinations were within normal limits.

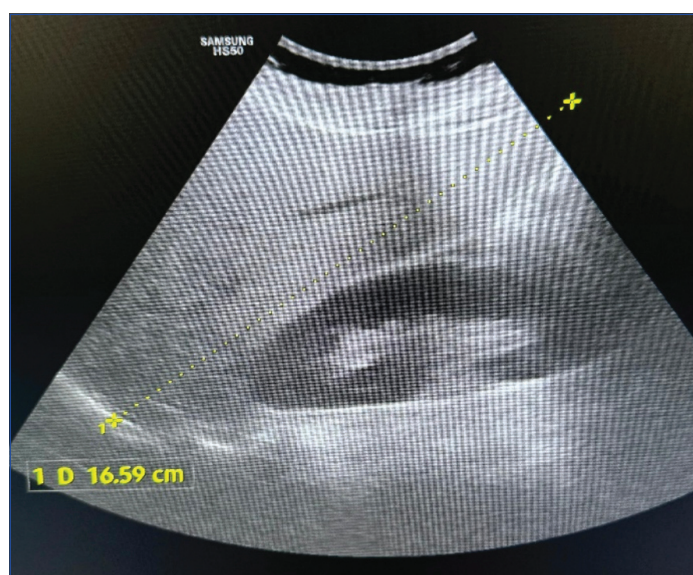Laboratory investigations on Day 1 [Table/Fig-1] [1] showed bicytopenia. The patient also had elevated bilirubin and Alanine Aminotransferase (ALT) levels, along with raised urea and creatinine levels. Additionally, the patient exhibited significant proteinuria with an elevated urinary albumin-creatinine ratio and a few red blood cells in the urine. The patient also showed signs and symptoms of rhabdomyolysis; therefore, serum Creatinine Phosphokinase (CK) was sent and found to be elevated at 1800 U/L. The patient's fever profile revealed the presence of only dengue and hepatitis A IgG. Rapid malarial antigen test, Widal test, serum Leptospira IgM, hepatitis E and serology tests were negative.

Ultrasonography of the abdomen and pelvis revealed an enlarged liver measuring 16.59 cm with altered echotexture and surface nodularity [Table/Fig-2a], a borderline enlarged spleen measuring 14.42 cm [Table/Fig-2b] and bilateral mildly raised renal cortical echogenicity.

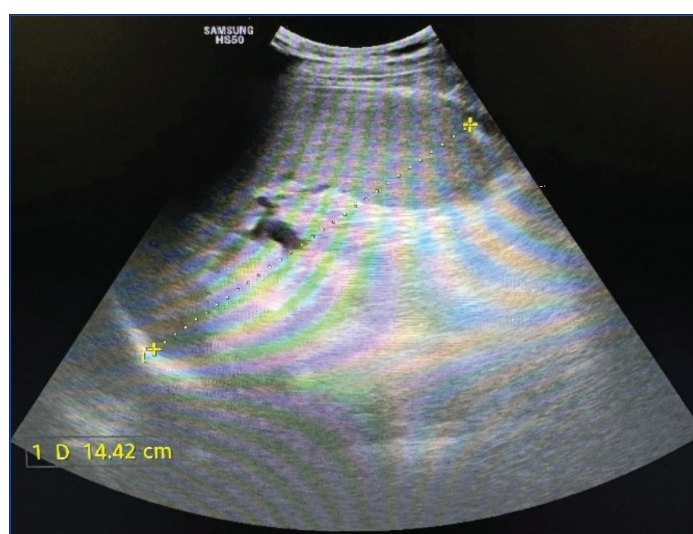Investigation	Reports- Day 1	Reports- Day 2	Reports- Day 3	Reports- Day 4	Reports- Day 8	Normal range [1]
Haemoglobin (g/dL)	9.2	7.2	9.3	9.1	9.5	12-16
White blood cells (/ μ L)	5800	6300	8900	7800	5200	4500-11000
Platelet count (/ μ L)	149000	159000	256000	259000	252000	150000- 400000
Haematocrit (%)	18.4	15.8	17.2	20.4	23.6	35-44.9
Mean corpuscular volume (fL)	97.2	100.2	101.2	98.6	92.6	78.2-97.9
Urea (mg/dL)	80.2	206	143	62	66	17-49
Creatinine (mg/dL)	2.8	8.33	4.95	3.33	1.88	0.6-1.2
Serum sodium (mmol/L)	137	135	137	139	137	136-145
Serum potassium (mmol/L)	4.1	4.4	3.54	3.67	3.88	3.5-5.1
Serum chloride (mmol/L)	101	97	97	102	99	98-107
Total bilirubin (mg/dL)	9.9	3.91	2.00	1.25	0.79	0.22-1.2
Direct bilirubin (mg/dL)	6.8	0.72	0.84	0.38	0.27	<0.5
Indirect bilirubin (mg/dL)	3.1	3.19	1.16	0.87	0.52	0.1-1

Aspartate Aminotransferase (AST) (U/L)	40.2	40.2	40	20	32	8-43
Alanine Aminotransferase (ALT) (U/L)	76.6	76.6	69	61	48	7-45
Creatinine Phosphokinase (CK) (U/L)	1800	960	872	64	52	55-170
Lactate Dehydrogenase (LDH) (U/L)	-	1933	1392	803	256	80-225
Urine routine microscopy (dipstick method) per high power field (hpf)	Protein- 3+ Glucose- trace Red blood cells- 2-3 Pus cells- 2-3 Epithelial cells- 1-2					
Glycosylated Haemoglobin % (HbA1C)	4.7					4-5.6
Stool occult blood	Negative					
Urinary albumin creatinine ratio by Jaffe method	633.10					<30
Serum calcium (mg/dL)	8.7					8.5-10
Serum magnesium (mg/dL)	1.96					1.4-2.2
Serum phosphorous (mg/dL)	3					4-6.5
Alkaline phosphatase (U/L)	107.4					50-117
Prothrombin time (seconds)	11.63					11-13
INR	1.02					<1.2

[Table/Fig-1]: Serial investigations and reports [1].



[Table/Fig-2a]: The yellow dotted line shows the extent of enlarged liver of size 16.59 cm.



[Table/Fig-2b]: The yellow dotted line shows the extent of enlarged spleen of size 14.42 cm.

Based on the clinical presentation, laboratory findings and radiological imaging on Day 1, the patient was initially suspected to have fever with thrombocytopenia secondary to viral aetiology, along with obstructive jaundice. After the fever profile results came back negative, the

patient was provisionally diagnosed with rhabdomyolysis secondary to infectious aetiology and urinary tract infection. The patient was started on injectable doxycycline and supportive intravenous fluid therapy. The patient's intake and output were monitored hourly.

Laboratory investigations were repeated on Day 2 [Table/Fig-1], as the patient had begun developing decreased urinary output. The reports revealed a suspicion of haemolytic anaemia, along with drastically elevated urea and creatinine levels suggestive of AKI. The patient underwent haemodialysis, along with fluid restriction due to decreased urine output, proteinuria and raised urea and creatinine levels. The patient's kidney function tests improved with dialysis. Intravenous antibiotics and supportive treatment were continued and further evaluation for the cause of haemolytic anaemia was conducted via special laboratory investigations. The patient was then transfused with blood along with dialysis.

Laboratory investigations were repeated on Day 3 [Table/Fig-1], which revealed a declining trend in renal and liver function tests, along with LDH. The peripheral blood smear showed fragmented red blood cells, raising suspicion of TTP. The patient's Thrombotic Microangiopathy (TMA) panel was sent on Day 3 to rule out TTP.

The patient was reviewed and another cycle of dialysis was performed under Packed Cell Volume (PCV) cover. Monitoring of the patient's intake and output continued, revealing decreased urinary output. The patient received ongoing treatment with antibiotics and supportive therapy. Steroid treatment was initiated with intravenous injection of methylprednisolone 500 mg for three days, given the suspicion of TTP.

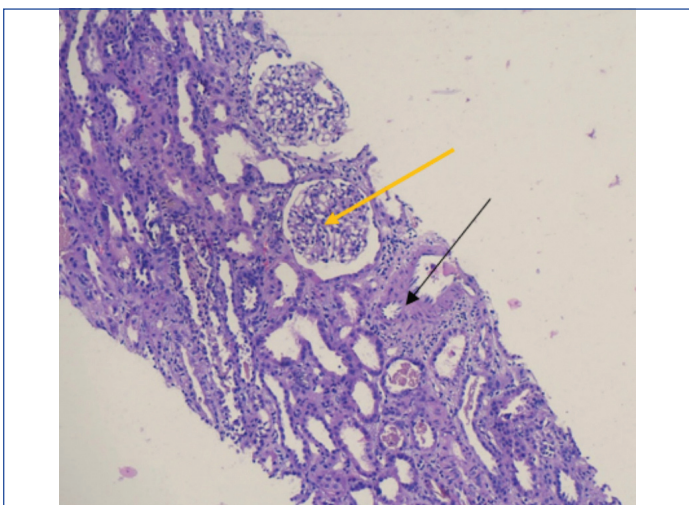
On Day 4, special laboratory investigations were conducted to evaluate the haemolytic anaemia, which included indirect and direct Coombs tests, complement factor 3 (mg/dL) and complement factor 4 (mg/dL) to investigate complement-induced glomerulonephritis, antinuclear antibody by immunofluorescence (ANA by IF) to explore autoimmune aetiology for renal dysfunction and an antineutrophil cytoplasmic antibodies (ANCA) profile to rule out associated vasculitis-induced glomerulonephritis; all the results were negative. Repeat laboratory reports showed a declining trend in CK and LDH levels [Table/Fig-1]. The TMA panel results were still awaited.

The patient continued to receive intravenous steroids, antibiotics and supportive therapy. He underwent alternate-day haemodialysis. From Day 4, the patient was treated with plasmapheresis, given the initial presentation of mental confusion with thrombocytopenia, fever, haemolytic anaemia and AKI, suggestive of TTP. Laboratory parameters were monitored daily.

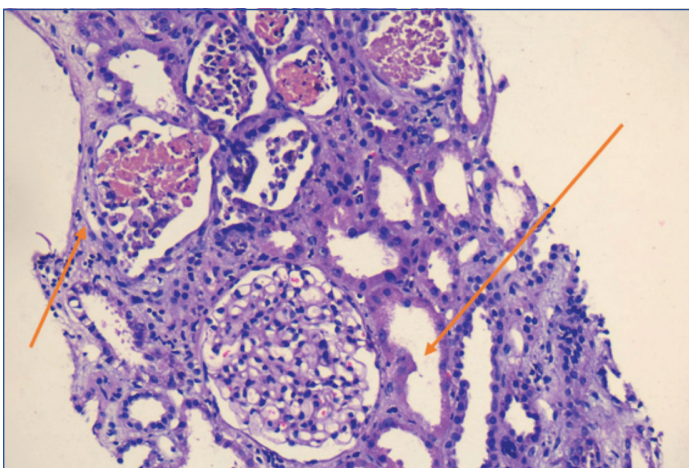
On Day 5, the TMA panel reports arrived, showing decreased activity of A Disintegrin and Metalloproteinase with Thrombospondin Type 1 Motif, Member 13 (ADAMTS13) at 0.06 IU/mL; other reports of the panel were within normal limits. The patient was diagnosed with TTP and received five cycles of plasmapheresis until Day 8, along with alternate-day haemodialysis.

On Day 8 [Table/Fig-1], laboratory parameters revealed mildly raised creatinine levels and anaemia. The patient was then taken for a renal biopsy to assess the stage of kidney disease and to plan for a transplant if needed.

The renal biopsy revealed cell debris casts seen with diffuse interstitial oedema marked with a black arrow and non proliferative morphology in the glomeruli marked with a yellow arrow on morphologic examination [Table/Fig-3a]. There was also severe acute tubular injury marked with orange arrows, showing several pigmented casts [Table/Fig-3b]. Immunofluorescent studies did not show significant glomerular or extraglomerular immune deposits.



[Table/Fig-3a]: Diffuse interstitial oedema marked with the black arrow and non proliferative morphology in glomeruli marked with yellow arrow (H&E, 10x).



[Table/Fig-3b]: Severe acute tubular injury marked with orange arrows (H&E, 40x).

The patient was stable after the renal biopsy and was discharged with a prescription for prednisone tablets at a dosage of 50 mg (1 mg/kg) for the initial four weeks, followed by a tapering schedule over the next four weeks. The patient was advised to return to the outpatient department for a review, which included blood sugar tests, renal function tests, a haemogram and electrolyte levels after five days.

Upon review, his laboratory parameters were within normal limits and he did not require further dialysis. The patient has been returning to the outpatient department for renal function tests once a month and has been informed about the risks of severe haemolytic anaemia and fluid overload, such as breathlessness, yellowish discoloration of the skin, decreased urine output and haematuria.

DISCUSSION

The TTP is a type of microangiopathic haemolytic anaemia identified by a pentad of symptoms: fever, haemolytic anaemia, thrombocytopenia and dysfunction of the renal and nervous systems. TTP arises from either a congenital or acquired deficiency of A Disintegrin and Metalloproteinase with thrombospondin type 1 motif, member 13 (ADAMTS13). Reduced ADAMTS13 activity leads to the formation of microthrombi, resulting in ischaemia and damage to vital organs, primarily affecting the central nervous system and kidneys. The worldwide incidence of TTP is 1.5 to 6 cases per million adults annually, with 90% of cases being adults and 10% being children [2]. TTP is a serious haematological emergency that poses a significant risk of mortality if not treated promptly. The results of a study conducted in an intensive care setting in India showed that TTP is more common among women, who also have a higher mortality rate [3].

Rhabdomyolysis is a serious medical condition characterised by the rapid breakdown of damaged skeletal muscle. This damage disrupts the muscle's structural integrity, causing the release of various intracellular substances such as myoglobin, CK, aldolase, Lactate Dehydrogenase (LDH) and electrolytes into the bloodstream and surrounding tissues [4].

The rare co-existence of rhabdomyolysis and TTP has been documented in medical literature. For example, Qahtani SA, reported a case involving a 39-year-old Sudanese man in Saudi Arabia who developed severe rhabdomyolysis alongside refractory TTP, resulting in AKI that necessitated intensive plasmapheresis and dialysis [5]. In this patient, elevated CK levels, dark-coloured urine and muscle weakness indicated that rhabdomyolysis was a key contributor to AKI, alongside haemolysis and microvascular thrombosis due to TTP. Renal biopsy findings of pigmented casts further confirmed rhabdomyolysis as a primary factor. Unlike the case described by Qahtani SA, where rhabdomyolysis stemmed from resistant TTP, this patient responded well to plasmapheresis, corticosteroids and supportive treatment, leading to the recovery of both renal and systemic functions.

Plasmapheresis remains central to the treatment of TTP, a point reinforced by Narayan SK et al., who documented its critical role in improving outcomes, especially when initiated early in an intensive care setting [3]. In this case, plasmapheresis was started promptly based on clinical suspicion, even before confirming ADAMTS13 activity, which was ultimately found to be severely deficient. Such a deficiency allows ultra-large von Willebrand factor multimers to persist, driving platelet aggregation and microvascular thrombosis, the hallmarks of TTP.

The use of corticosteroids alongside plasmapheresis was instrumental in this patient's treatment, helping to reduce systemic inflammation and control the autoimmune aspect of TTP. This therapeutic combination halted microangiopathic progression and achieved haematologic remission. Lee J et al., also reported a similar case in which the combination of plasmapheresis and immunosuppressive therapy significantly improved survival in a 70-year-old Korean patient with TTP, rhabdomyolysis, AKI and hypothyroidism [6]. Furthermore, alternate-day haemodialysis was essential to manage AKI in this case, maintaining fluid-electrolyte balance and preventing complications such as pulmonary oedema.

The patient was initially suspected of having fever with thrombocytopenia secondary to viral aetiology, along with obstructive jaundice based on the investigations. After the fever profile returned negative, the patient was provisionally diagnosed with rhabdomyolysis secondary to an infectious aetiology and urinary tract infection. This case presented additional complexity due to overlapping features of infectious causes, rhabdomyolysis and MAHA. The confirmation of TTP through a TMA panel, which showed ADAMTS13 levels below 10%, was crucial in establishing the diagnosis.

Another notable case, reported by Kamura Y et al., described a Japanese man who developed TTP triggered by his first dose of the mRNA-1273 vaccine, initially presenting with rhabdomyolysis [7]. In this patient, symptoms such as fever, abdominal pain, dark urine, elevated CK and high LDH levels initially pointed toward rhabdomyolysis. However, concurrent findings of anaemia, thrombocytopenia and MAHA prompted further investigation, which revealed the underlying TTP. Recognising this uncommon overlap between rhabdomyolysis and TTP is critical for timely diagnosis and intervention.

This case also underscores the difficulty in distinguishing infectious triggers from primary haematologic conditions. Although initial serological tests for dengue and hepatitis suggested prior exposure, they did not explain the severity of this presentation. The renal biopsy showed acute tubular injury with pigmented casts, highlighting the multifactorial nature of the renal damage caused by TTP and rhabdomyolysis.

This case highlights the importance of early recognition and multidisciplinary management of TTP in a young patient with overlapping complications, including rhabdomyolysis, AKI and severe haemolytic anaemia. The timely initiation of plasmapheresis, haemodialysis and corticosteroid therapy, guided by clinical suspicion and confirmatory laboratory investigations, proved life-saving.

The diagnostic challenges posed by overlapping symptoms underscore the need for vigilance in identifying microangiopathic haemolytic anaemia in critically ill patients. The favourable outcome in this case emphasises the significance of early intervention and continuous monitoring to prevent long-term sequelae, ensuring a good prognosis in such complex and rare conditions.

CONCLUSION(S)

This case demonstrates the importance of maintaining a high index of suspicion and acting promptly when young patients present with overlapping haematologic and renal abnormalities. The successful outcome achieved here, despite the complexity of the presentation, emphasises the value of early plasmapheresis, corticosteroids, supportive care and a multidisciplinary approach in managing TTP and its associated complications. This contrasts with previous cases where delayed diagnosis resulted in worse outcomes, highlighting the importance of vigilance and rapid intervention in similar clinical scenarios.

REFERENCES

[1] American Board of Internal Medicine. ABIM laboratory test reference ranges January 2024 [Internet]. Philadelphia (PA): American Board of Internal Medicine; 2024. Available from: <https://www.abim.org/laboratory-test-reference-ranges>.

[2] Nuñez Zuno JA, Khaddour K. Thrombotic thrombocytopenic purpura evaluation and management. In: StatPearls [Internet]. Treasure Island (FL): StatPearls Publishing; 2024 Jan-. [Updated 2023 Sep 27]. Available from: <https://www.ncbi.nlm.nih.gov/books/NBK470585/>.

[3] Narayan SK, Gudivada KK, Sivakoti S, Krishna B. Outcomes of patients with thrombotic thrombocytopenic purpura treated in an intensive care unit. Natl Med J India. 2023;36:295-300. Doi: 10.25259/NMJL_205_21.

[4] Torres PA, Helmstetter JA, Kaye AM, Kaye AD. Rhabdomyolysis: Pathogenesis, diagnosis, and treatment. Ochsner J. 2015;15(1):58-69. PMID: 25829882; PMCID: PMC4365849.

[5] Qahtani SA. Acute renal failure and severe rhabdomyolysis in a patient with resistant thrombotic thrombocytopenic purpura. Int J Gen Med. 2011;4:687-89. Epub 2011 Oct 4. Doi: 10.2147/IJGM.S20815. PMID: 22069369; PMCID: PMC3206110.

[6] Lee J, Lee KW, Yun SM, Shin HC, Nam SM, Cho NY. Thrombotic thrombocytopenic purpura and rhabdomyolysis associated with acute renal failure in hypothyroidism. J Korean Geriatr Soc. 2014;18(1):39-43. Doi: 10.4235/jkgs.2014.18.1.39. Available from: <https://www.e-agmr.org/journal/view.php?number=570>.

[7] Kamura Y, Terao T, Akao S, Kono Y, Honma K, Matsue K. Fatal thrombotic microangiopathy with rhabdomyolysis as an initial symptom after the first dose of mRNA-1273 vaccine: A case report. Int J Infect Dis. 2022;117:322-25. Epub 2022 Feb 18. Doi: 10.1016/j.ijid.2022.02.031. PMID: 35189339; PMCID: PMC8853962.

PARTICULARS OF CONTRIBUTORS:

- 1. Associate Professor, Department of Internal Medicine, Dr. D. Y. Patil Medical College, Hospital and Research Centre, Dr. D. Y. Patil Vidyapeeth, Sant Tukaram Nagar, Pimpri, Pune, Maharashtra, India.
- 2. Junior Resident, Department of Internal Medicine, Dr. D. Y. Patil Medical College, Hospital and Research Centre, Dr. D. Y. Patil Vidyapeeth, Sant Tukaram Nagar, Pimpri, Pune, Maharashtra, India.
- 3. Professor, Department of Internal Medicine, Dr. D. Y. Patil Medical College, Hospital and Research Centre, Dr. D. Y. Patil Vidyapeeth, Sant Tukaram Nagar, Pimpri, Pune, Maharashtra, India.
- 4. Junior Resident, Department of Internal Medicine, Dr. D. Y. Patil Medical College, Hospital and Research Centre, Dr. D. Y. Patil Vidyapeeth, Sant Tukaram Nagar, Pimpri, Pune, Maharashtra, India.
- 5. Junior Resident, Department of Internal Medicine, Dr. D. Y. Patil Medical College, Hospital and Research Centre, Dr. D. Y. Patil Vidyapeeth, Sant Tukaram Nagar, Pimpri, Pune, Maharashtra, India.

NAME, ADDRESS, E-MAIL ID OF THE CORRESPONDING AUTHOR:

Dr. Sheetal Nandha Kishore,
A22, Old Girls Carnation Hostel, Dr. D. Y. Patil Medical College and Hospital, Pimpri,
Pune-411018, Maharashtra, India.
E-mail: sheetalbackup22@gmail.com

AUTHOR DECLARATION:

- Financial or Other Competing Interests: None
- Was informed consent obtained from the subjects involved in the study? Yes
- For any images presented appropriate consent has been obtained from the subjects. Yes

PLAGIARISM CHECKING METHODS: [Jain H et al.]

- Plagiarism X-checker: Jan 29, 2025
- Manual Googling: Mar 01, 2025
- iThenticate Software: Mar 08, 2025 (8%)

ETYMOLOGY: Author Origin

EMENDATIONS: 6

Date of Submission: Jan 28, 2025
Date of Peer Review: Feb 24, 2025
Date of Acceptance: Mar 11, 2025
Date of Publishing: Apr 01, 2025